Dr.Adnan Tawfiq Al-Bajalan
M.B.CH.B , MSc Cardiology (Egypt)

Anatomy of heart and graet vessels

Aims of this session :

- To provide an overview of the structure and function of the cardiovascular system.
- To emphasise the need for apropriate blood flow to different tissues of the body and the functional elements in the cardiovascular system which are necessary to provide it.
- To study and appreciate the position of heart in situ.
- To study the external features of the heart and major vessels, and to appreciate the course of blood flow into and out of the heart.
- To study the structure of different types of blood vessels in relation to their function in supplying blood to and from the tissues of the body.

Learning outcomes :

By the end of this lecture you should be able to:

- Describe the factors influencing the exchange of substances between the blood in capillaries and the surrounding tissues.
- Describe the critical importance of adequate blood flow for the maintenance of capillary exchange.
- Describe the distribution of cardiac output over major organs of the body.
- Describe the major functional components of the circulation.
- Describe the distribution of blood volume over the major parts of the circulation.

Introduction :

The heart lies in the middle mediastinum; the mediastinum is the intervening region between the right and left pleural cavities occupied by the lungs in the thoracic cavity.

The middle mediastinum consists of the pericardial sac containing the heart and its blood vessels (**coronary vessels**) and the roots of the aorta, superior and inferior vena cava and the pulmonary vessels

Surface Anatomy of the Heart

The heart is shaped roughly like a cone and consists of four muscular chambers.

The right and left ventricles: are the main pumping chambers.

The right and left atria : deliver blood to their respective ventricles.

The apex is formed by the tip of the left ventricle

The base or posterior surface of the heart is formed by the atria, mainly the left.

The anterior surface of the heart is shaped by the right atrium and ventricle.

The inferior surface of the heart is formed by both ventricles, primarily the left.

The bounderies of the heart

- **The right border is established by** the right atrium and the superior and inferior venae cavae.
- **The inferior border is** formed mainly by the right ventricle.
- **The left border is** formed by left ventricle and a portion of the left atrium.
- **The superior border is** shaped by both atria.

Cardiovascular module

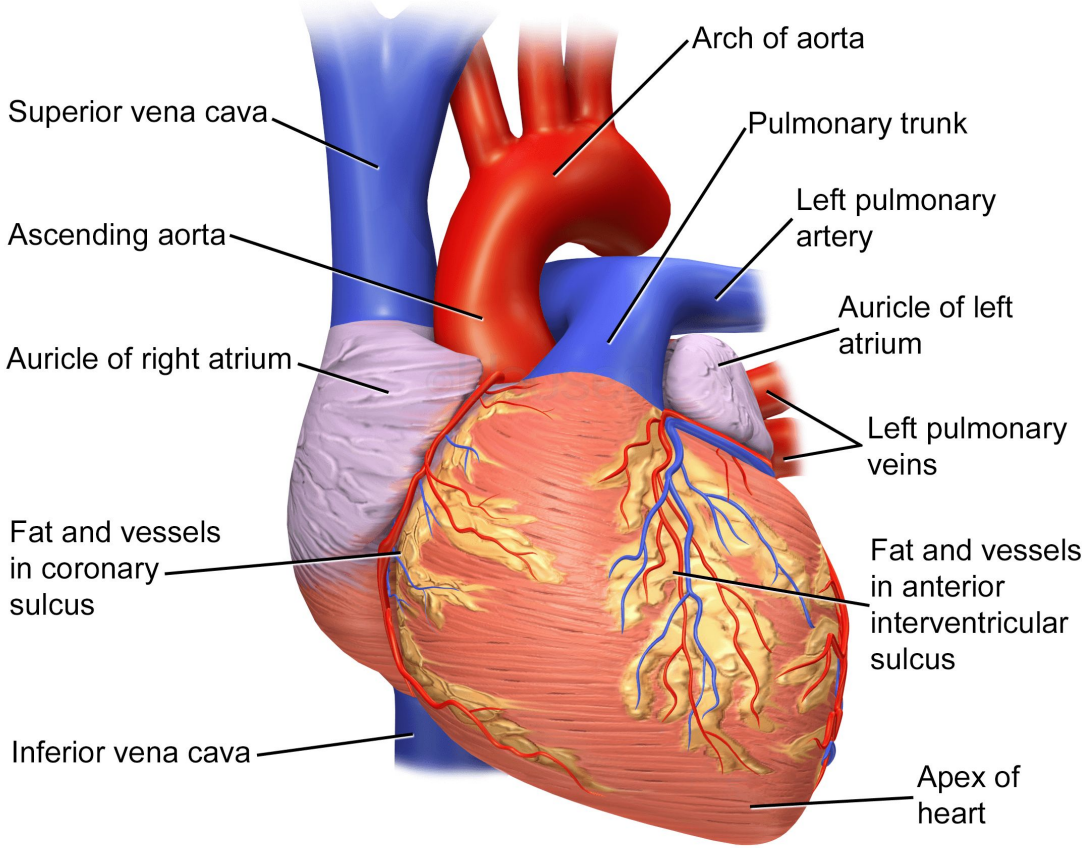

Superficial Heart Anatomy (Anterior)

Internal Structure of the Heart

1 Four major valves in the normal heart direct blood flow in a forward direction and prevent backward leakage.

1-Aortic valve

2-Mitral valve

3-Tricuspid valve

4-Pumonary valve

The cardiac wall consist of 3 layaers : from inside to outside

1-Endocardium: single layer of endothelial cells.

2-Myocardium : Is the thickest layer of the heart and consists of bundles of cardiac muscle cells.

3-Epicardium : External to the myocardium is a layer of connective tissue and adipose tissue.

Right Atrium and Ventricle

Right Atrium: superior and inferior venae cava are opening into it.

The interatrial septum : it seperate right and left atrium.

The right ventricle is roughly triangular in shape, the wall is more trabeculated except for its outlet which is smooth.

Left Atrium and Ventricle

Left atrium : four pulmonary veins enter left atrium , left atrium opens into left ventricle through the mitral valve..

Left Ventricle : The cavity of **the left ventricle** is approximately cone shaped and longer than that of the right ventricle. In a healthy adult heart, the wall thickness is 9 to 11 mm, roughly three times that of the right ventricle..

The interventricular septum is the thick wall between the left and right ventricles.

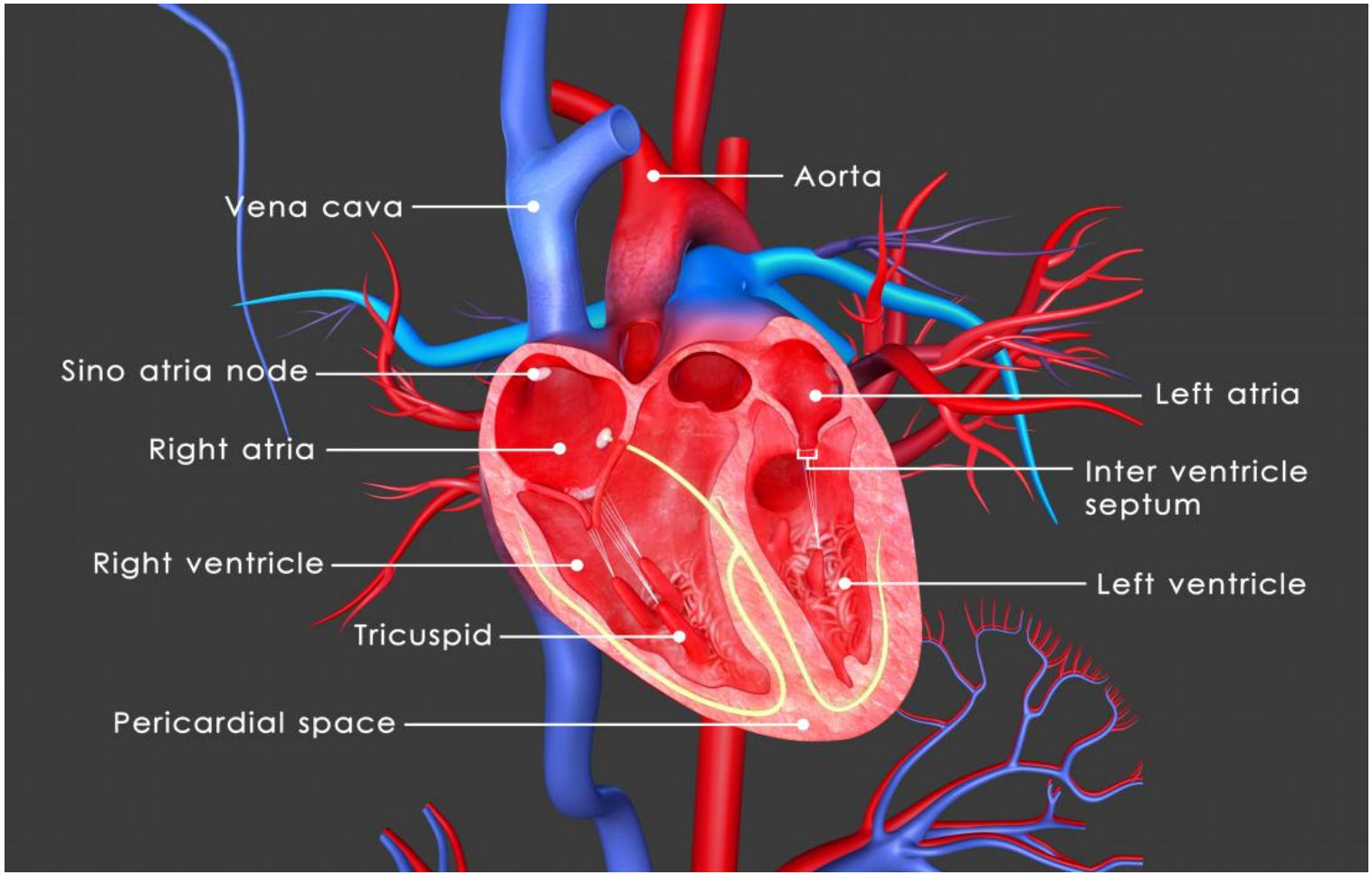
Aorta
Vena cava
Sino atria node
Left atria
Right atria
Inter ventricle
septum
Right ventricle
Left ventricle
Tricuspid
Pericardial space

Impulse-Conducting System

Consists of specialized cells that initiate the heartbeat and electrically coordinate contractions of the heart chambers.

The sinoatrial node (SA) is a small mass of specialized cardiac muscle fibers in the wall of the right atrium. It is located to the right of the superior vena cava entrance and normally initiates the electrical impulse for contraction.

The atrioventricular node (AV) lies beneath the endocardium in the inferoposterior part of the interatrial septum.

The bundle of His, distal to AV node ,it perforates the interventricular septum posteriorly. Within the septum, the bundle of His bifurcates into a broad sheet of fibers that continues over the left side of the septum, known as the **left bundle branch**, and a compact, cablelike structure on the right side, **the right bundle branch**. Theses branhes are subdivided and forming subendocardial plexuses which send distributing **purkinje fibers** to ventriculr muscle.

Conducting System

- Network of specialized tissue that stimulates contraction
- Modified cardiac myocytes
- The heart can contract without any innervation

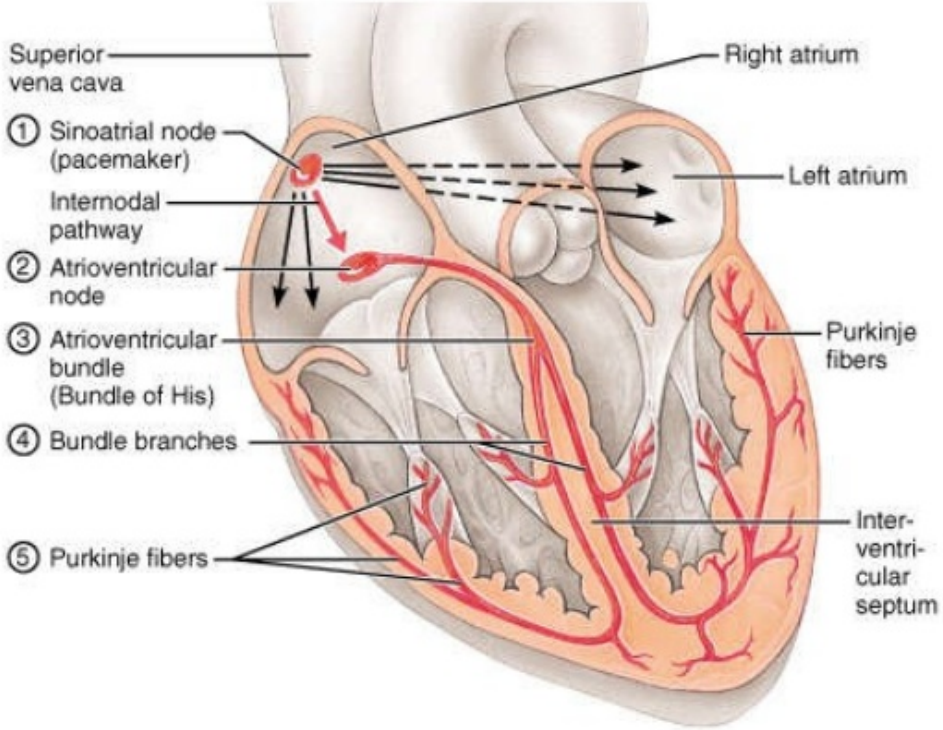

- Major Arteries & Veins of the Body

head and neck :

- Brachiocephalic trunk
- Common Carotid.
- External Carotid & its branches
- Facial artery
- Maxillary artery
- Superficial temporal artery/
- Internal Carotid

The thorax :

- Thoracic [Descending] Aorta &
- its Intercostal branches

The abdomen :

- Abdominal Aorta & its paired branches:
- Suprarenal arteries
- Renal arteri
- Ovarian/Testicular arteries & its unpaired branches
- Celiac artery
- Superior Mesenteric artery
- Inferior Mesenteric artery and the pelvis
- Common Iliac artery
- External Iliac artery
- Internal Iliac artery

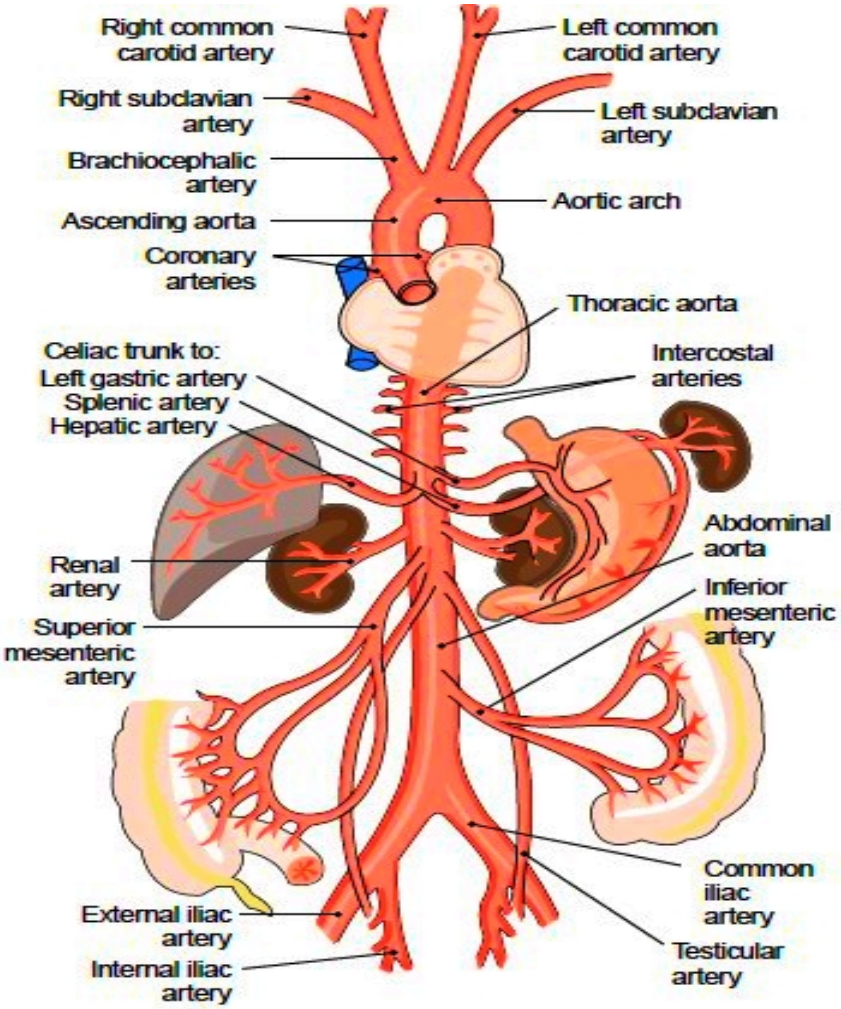
Right common carotid artery
Left common carotid artery
Right subclavian artery
Left subclavian artery
Brachiocephalic artery
Aortic arch
Ascending aorta
Coronary arteries
Thoracic aorta
Celiac trunk to:
Left gastric artery
Splenic artery
Hepatic artery
Intercostal arteries
Abdominal aorta
Renal artery
Inferior mesenteric artery
Superior mesenteric artery
Common iliac artery
External iliac artery
Internal iliac artery
Testicular artery

- The major veins of the upper limb (Subclavian, Cephalic, Basilic and Median Cubital veins) and the lower limb (Femoral, Long Saphenous,Short Saphenous and Popliteal veins) will be studied further in the Musculoskeletal System Module.

The cardiovascular system as a whole must :

- Deliver between 5 and 25 l.min-1 of blood to the body
- Maintain a blood flow of 750 ml.min-1 to the brain at all times
- Maintain blood flow to the heart muscle and kidneys at all times

Meeting this specification requires :

- A pump - obviously the heart
- Distribution vessels - the arteries
- Flow control - the output of the pump (the 'cardiac output') must be distributed appropriately by restricting flow to those parts of the body which are easy to perfuse so as to drive blood to those, often vulnerable, parts which are not so easy to get blood to. Flow control is via resistance vessels - the arterioles and pre capillary sphincters
- Ability to cope with changes in the cardiac output. This requires **capacitance** in the system - a 'store' of blood that can be called upon to cope with temporary imbalances between the amount of blood returning to the heart and the amount that it is required to pump out. This store is in the veins.

- At rest, the blood volume of about 5 liters is distributed as follows:

  11% in the arteries and arterioles, 5% in the capillaries, 17% in the heart and lungs, 67% in the veins.

- The cardiovascular system serves to supply cells in the body with their metabolic needs which requires a system of distribution of materials and exchange with the tissues.

- **Exchange** with the tissues occurs at the capillaries, which are vessels lined with a single layar of endothelial cells through which many substances may diffuse easily, 98% of echange is by diffusion.

- **Diffusion is affected by:**

  - The area available for exchange
  - The difficulty of movement through the barrier (**diffusion resistance**)
  - The concentration difference (Gradient

- The area availabe for exchange in a tissue is determined by how many capillaries there are per unit volume(**the capillary density**). This varies from tissue to tissue and is highest in the most metabolically active. **Not all capillaries** are always perfused,so it represents the maximum area for exchange. Generally.however, area is not limiting.

- **Resistance** is determined by the nature of the barrier and the molecules which are diffusing. Lipid soluble molecules diffuses easily through capillary cell membranes , hydrophilic molecules travel via pores which offer little resistance to small molecules and ions, but prevent movement of molecules where molecular weight exceeds 60.000. For small molecules ,diffusion resistance , therefore, is not limiting

- **Thanks for your listening and attention**